



PATIENT

Coco Boyd

PRESENTING CLINICAL SIGNS

History: Persistent cough. No heart murmur.
-Radiographs: Showed enlarged heart and bronchointerstitial pattern.

SPECIES

Canine

ECHOCARDIOGRAM FINDINGS

2D, m-mode, color flow and doppler imaging is available. Normal mitral valve leaflets with no prolapse into the left atrial lumen. No mitral regurgitation with no left atrial dilation. Normal LV diameter with adequate myocardial function. The tricuspid valve appears normal with trivial tricuspid regurgitation. Normal right atrial and ventricular diameter and morphology indicating no overt evidence of pulmonary arterial hypertension. The pulmonic and aortic valves are normal in morphology and mobility. Normal pulmonic and aortic outflow velocities with laminar flow. No obvious aortic or pulmonic insufficiency. No pericardial or pleural effusion noted. No obvious cardiac masses.

BREED

Labrador Retriever

SEX

Female Spayed

CARDIAC CHART

AGE

7 years

WEIGHT

38.3lbs

INTERPRETED BY

Maggie Machen Lamy,
DVM, DACVIM
(Cardiology)

IMAGING PERFORMED BY

Jacque Pankatz,
DVM

HOSPITAL NAME

Mountain Vista
Veterinary Hospital

REFERRING VET

Dr. Pankatz

INVOICE

29389

DATE

3/5/23

CANINE CARDIAC PARAMETERS	MR VMAX (m/s)	TR VMAX (m/s)	LA/AO (Boon method)	LA/AO (Heart Base; Swe)	FS (%)	EF (%)	EPSS (cm)
NORMAL PARAMETER	4.5-5.5	<2.7	1.3	<1.6	28-40	40-100	<0.6
PATIENT	NA	NM	1.4	1.2	48	79	0.1
CANINE CARDIAC PARAMETERS	HR (BPM)	AV VMAX (m/s)	PV MAX (m/s)	BODY WEIGHT (kg)	LA 2D short axis Base view (cm)	LVIDd Avg; 2D and m-mode short axis (cm)	LVIDs Avg; 2D and m-mode short axis (cm)
NORMAL PARAMETER	50-100	0.7-1.7	0.7-1.6	BELOW	BELOW	BELOW	BELOW
PATIENT	NM	1.8	1.1	17.4	3.2	5.0	2.6
*Normal chamber parameters expressed as a mean value (SD)				3	1.27 (5.3)	2.46 (2.46)	1.36 (5.5)
BODY WEIGHT DEPENDENT PARAMETERS				5	1.40 (4.5)	2.74 (5.2)	1.60 (4.7)
<i>*Note: All measurements based upon multi-modal images and methods. An average value is reported.</i>				10	1.50 (3.8)	3.27 (3.5)	2.06 (3.1)
				15	1.83 (2.0)	3.71 (2.4)	2.43 (2.1)
				20	2.02 (1.9)	4.14 (2.2)	2.80 (2.0)
				25	2.18 (2.4)	4.48 (2.9)	3.10 (2.5)
				30	2.33 (3.3)	4.83 (3.9)	3.39 (3.4)
				35	2.48 (4.3)	5.17 (5.0)	3.69 (4.5)
				40	2.62 (5.2)	5.48 (6.1)	3.96 (5.4)
				50	2.88 (7.1)	6.07 (8.3)	4.46 (7.4)

INTERPRETATION OF THE FINDINGS & FURTHER RECOMMENDATIONS

Overtly normal cardiac dimensions and function, with no obvious dysfunction or dilation of the left heart. No significant valvular leaks are visualized, and no evidence of pulmonary hypertension.

No cardiac medications are indicated at this time as the cough appears non-cardiac in origin. Continued work up for infectious/inflammatory respiratory causes is recommended. Options include Baytril or similar antibiotic, anti-inflammatory prednisone, aggressive hydrocodone, etc. If refractory, may consider TTW/BAL for further information.



PATIENT

Coco Boyd

Monitor for development of a heart murmur, cough, labored breathing, exercise intolerance or collapse episodes.

SPECIES

Canine

Chronic respiratory issues can lead to pulmonary hypertension if poorly controlled and a recheck echocardiogram is recommended should any exertional syncope/dyspnea occur, or a murmur be noted in the future.

BREED

Labrador Retriever

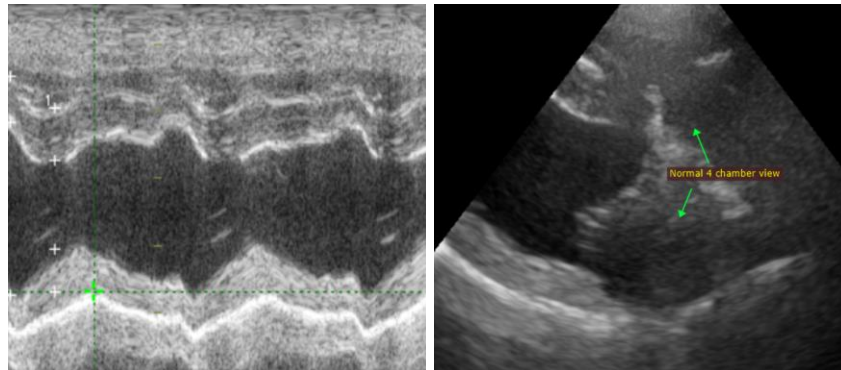
SEX

Female Spayed

AGE

7 years

IMAGES



WEIGHT

38.3lbs

The information and recommendations provided are based on the images presented by the referring veterinarian. No evaluation can be communicated regarding pathology that was not visible in the image/video clips provided.

INTERPRETED BY

Maggie Machen Lamy,
DVM, DACVIM
(Cardiology)

Thank you for this referral. This report was generated using transcription software, and minor dictation errors may be present. If the clinical or image interpretation does not parallel your findings or if I can be of any further assistance please contact me.

Maggie Machen Lamy, DVM
Diplomate of the American College of Veterinary Internal Medicine (Cardiology)
info@sonopath.com

IMAGING PERFORMED BY

Jacque Pankatz,
DVM

HOSPITAL NAME

Mountain Vista
Veterinary Hospital

REFERRING VET

Dr. Pankatz

INVOICE

29389

DATE

3/5/23